

Short communication

***Ehrlichia Canis* Infection in a Labrador retriever Dog: A Case Report**

ABSTRACT

A six-year-old Labrador retriever dog with a history of fever, inappetence, and unilateral epistaxis was presented to the Referral Veterinary Clinical Complex, Indian Veterinary Research Institute, Izatnagar. Clinical examination revealed the dog had pyrexia, an enlarged peripheral lymph node, and the presence of ticks on the body. The dog was suspected of having a haemoprotozoan infection, and a thin peripheral blood smear was submitted to the Division of Parasitology, Indian Veterinary Research Institute, Izatanagar, Bareilly, for examination. A blood smear was screened for haemoprotozoan examination using Giemsa's stain, which showed positivity for *Ehrlichia canis*. Treatment was initiated with Doxycycline at 10 mg/kg B.wt. orally once for 28 days, along with supportive therapy, which resulted in a significant improvement in the dog's condition. An incidence of *E. canis* was reported from the Bareilly district of Uttar Pradesh.

Keywords: Ehrlichia canis, Dog, Doxycycline, Rickettsia, haemoprotozoan, etc.

1. INTRODUCTION

Ehrlichiosis is caused by a group of emerging rickettsial tick-borne infectious agent of public health importance, which are gram-negative obligate intracellular bacteria of the genus *Ehrlichia*, family *Anaplasmataceae* [1]. The parasite is spread via the bite of the brown dog tick, *Rhipicephalus sanguineus*, and causes severe clinical signs in affected animals [2]. Infection with *E. canis* primarily occurs during the warm season, when the vector tick is active [3].

The brown dog tick is the primary vector of *E. canis*, transferring the infection across hosts via blood feeding. The pathogenesis begins with an 8 to 20-day incubation period [4], followed by acute, subclinical, and, in some cases, chronic phases. Once transmitted, *E. canis* infects mononuclear phagocytic cells mostly monocytes. Infected monocytes typically have one or two morulae which can be demonstrated on peripheral blood smear [5].

The disease is clinically distinguished by fever, anorexia, lymphadenopathy, and a sharp reduction in cellular blood components, most commonly thrombocytopenia [6]. In this study, a dog infected with *Ehrlichia canis* was diagnosed conventionally, and the prevalence and control methods in India were discussed.

Clinical Presentation of the Animal: A six-year-old Labrador retriever breed of dog was presented to Referral Veterinary Clinical Complex, with the history of fever, inappetence and unilateral epistaxis. Thorough clinical examination of the dog revealed that dog had pyrexia (103.9°F), peripheral lymphadenopathy, petechial hemorrhages on the ventral abdomen and ticks found on the body. The animal was suspected for haemoprotozoan infection and thus thin

peripheral blood smear prepared from ear vein was sent to the Division of Parasitology, Indian Veterinary Research Institute, Izatanagar, Bareilly for haemoprotozoan examination.

Laboratory Examination:

A 1mL blood sample was obtained in an EDTA vial and sent to the laboratory. A routine complete blood count revealed anaemia (Hb: 7.5mg/dL) and thrombocytopenia (57000/cmm). A blood sample also tested positive for *Ehrlichia canis* by PCR.

2. MATERIALS AND METHODS

After fixing the thin blood smear for one minute in methanol, the sample was stained with Giemsa's stain at a dilution of 1:10 with water, forming a working solution, and was maintained for 40minutes. The slide was then rinsed with tap water, dried, and focused using a compound binocular light microscope with oil immersion. Microscopic examination of thin blood smear stained with Giemsa stain showed presence of pale blue bodies in the monocytes which were suggestive of morulae of *Ehrlichia canis* as shown in the Fig. 1

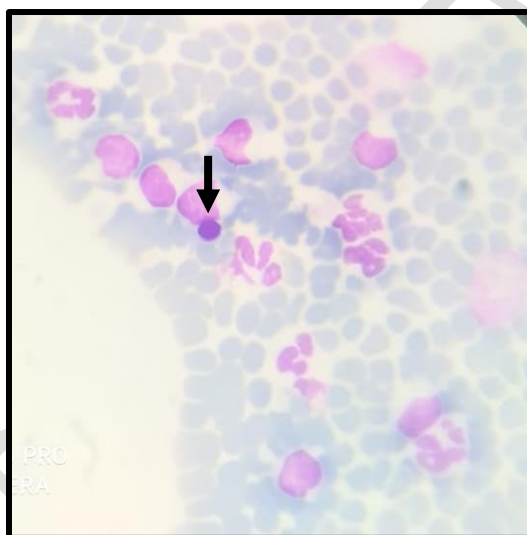


Fig. 1 *Ehrlichia Canis* morulae in monocytes stained with Giemsa's stain (1000X)

Treatment Protocol:

Based on history, clinical examination and laboratory investigation findings, the present case was diagnosed as a case of *Ehrlichia Canis* infection in a dog. Treatment was initiated according to standard protocol using Doxycycline at the dose rate of 10 mg/Kg. B.wt once daily orally for 28 days and Pantoprazole at the dose rate of 1 mg/Kg. B.wt once daily orally for 28 before food. Supportive therapy consisting of fluid therapy, styptics, hematinics and carioca papaya extract was also initiated. To combat tick infestation spot on Fipronil and S-Methoprene was applied topically. A significant improvement in the condition of animal was noticed after 28days of therapy. Again, peripheral blood smear examination was negative for *Ehrlichia Canis*.

3. RESULTS AND DISCUSSION

Brouqui and Raoult [7], Gahalot *et al.* [8] and Sinha *et al.* [9] reported that doxycycline and short and long acting tetracycline are effective in the successful management of *E. Canis* infection in a

dogs. The treatment of *E. canis* infections is considered effective when dogs improve clinically, haematology and biochemistry results return to regular, and the microorganism is no longer detectable in the body. Behera *et al.* [10] revealed that the nested polymerase chain reaction proved to be highly sensitive in detecting acute cases, followed by the buffy coat and blood smear examination. Singla *et al.* [11] found that *E. canis* is second most tick born pathogen affecting dog following *B. gibsoni* in a Punjab state of India. He also added that infection rate is higher during pre-monsoon season that is summer.

Neer *et al.* [12] concluded that even after complete recovery from an infection, animals do not get lifelong immunity, and there is still a risk of reinfection. Aziz *et al.* [13] suggested that control of vector by spraying suitable acaricides at regular intervals, physical removal of ticks, or monitoring of environmental parameters associated with tick proliferation, are key control measures in combating *Ehrlichiosis*.

4. CONCLUSION

Early diagnosis of *E. canis* is important for successful treatment at an early stage, preventing a chronic course. Therapeutic management with doxycycline along with supportive therapy could be useful for the management of *E. canis*-infected dogs.

REFERENCES

1. Jafarbekloo A, Bakhshi H, Faghihi F, Telmadarraiy Z, Khazeni A, Oshaghi MA, Ramzgouyan MR, Sedaghat MM. Molecular detection of Anaplasma and Ehrlichia infection in ticks in borderline of Iran-Afghanistan. *J. Biomed. Sci. Eng.* 2014; 25:7(11):919.
2. Groves MG, Dennis GL, Amyx HL, Huxsoll DL. Transmission of Ehrlichia canis to dogs by ticks (Rhipicephalus sanguineus). *Am. J. Vet. Res.* 1975; 1:36(7):937-40.
3. Dantas-Torres F. Biology and ecology of the brown dog tick, Rhipicephalus sanguineus. *Parasites vectors.* 2010; 3(1):1-1.
4. Rabon CM. *Transmission of low passage Ehrlichia canis to dogs by naturally fed and experimentally injected Rhipicephalus sanguineus ticks* (Doctoral dissertation, University of Georgia).
5. Dubie T, Mohammed Y, Terefe G, Muktar Y, Tesfaye J. An insight review on canine ehrlichiosis with emphasis on its epidemiology and pathogenesis importance. *GJVMR.* 2014; 2(4):59-67.
6. Ramakant RK, Verma HC, Diwakar RP. Canine ehrlichiosis: A review. *J. Entomol. Zool. Stud.* 2020; 8(2):1849-52.
7. Brouqui PH, Raoult DI. In vitro susceptibility of Ehrlichia sennetsu to antibiotics. *Antimicrob. Agents Chemother.* 1990; 34(8):1593-6.
8. Gahalot SC, Meena DS, Singh R, Singh YP, Mali MM, Bargurjar J, Jeph N, Meena S. Therapeutic management of canine ehrlichiosis in a german shepherd bitch: a case report. *Res. J. Vet. Pract.* 2017; 5(4):37-9.
9. Sinha S, Maiti SK, Ratre HK, Kalim MO, Bante N, Chourasia R, Mishra R, Reddy B. Therapeutic management of canine ehrlichiosis in a Rottweiler: A case report.

10. Behera SK, Dimri U, Banerjee P. *et al.* Molecular Detection and Assessment of Hemato-Biochemistry, Oxidant/Antioxidant Status in Natural Canine Monocytic Ehrlichiosis Cases from Northern India. *Proc. Natl. Acad. Sci., India, Sect. B Biol. Sci.* 2017;87:361–368.
11. Singla L, Sumbria D, Mandhotra A, Bal M, Kaur P. Critical analysis of vector-borne infections in dogs: *Babesia vogeli*, *Babesia gibsoni*, *Ehrlichia canis* and *Hepatozoon canis* in Punjab, India. *Acta Parasitologica.* 2016; 61(4): 697-706.
12. Neer TM, Breitschwerdt EB, Greene RT, Lappin MR. Consensus Statement on Ehrlichial Disease of Small Animals from the Infectious Disease Study Group of the ACVIM. *J. Vet. Intern. Med.* 2002; 16:309–315.
13. Aziz MU, Hussain S, Song B, Ghauri HN, Zeb J, Sparagano OA. Ehrlichiosis in dogs: A comprehensive review about the pathogen and its vectors with emphasis on south and east Asian countries. *Vet. Sci.* 2022; 29:10(1):21.

UNDER PEER REVIEW