

# Histopathological Evaluation of the Teratogenic Potential of Lixisenatide on the Cerebral Cortex of Developing Chick Embryo

**Abstract:** Background and Objectives- Chick embryos are commonly used in research to investigate the negative impacts of various drugs. One drug, lixisenatide, is superior to other GLP1 receptor antagonists for treating type 2 diabetes mellitus. However, the specific impact of lixisenatide on the developing cerebral cortex of the chick embryo remains unclear. Therefore, further research is necessary to fully understand the potential adverse effects of lixisenatide on brain development. **Materials and Methods-** it's an experimental study done at the Department of Anatomy, Santosh Medical College, Ghaziabad, Uttar Pradesh. The study aimed to investigate the effects on specific parameter in two groups, a control group, and an experimental group. The expected mean  $\pm$  SD of the parameter for the control and experimental groups were found to be  $27\pm 5.32$  and  $32\pm 5.30$ , respectively, based on a literature survey and pilot study. To achieve appropriate sample size, G\*Power software was used, with an alpha level of 5% and a power of 95.36%, which resulted in an effect size of 1.961 and a sample size of 28 for each group, leading to a total sample size of 280. The chick embryos first sacrificed then dissected, and the brain was separated and kept in a 10% formaldehyde solution. To identify histological characteristics of the cerebral cortex, the light and compound microscope were used for sections. **Result-** During the experiment, Lixisenatide induced necrotic changes and cellular condensation in chick embryo's cerebral cortex, specifically in groups C, D, and E. Additionally, there was mild distortion found in the cortex indicating degenerative changes experimental group E. There was a statistically significant increase in histopathological changes observed in the cerebral cortex as the dose of Lixisenatide increased in each experimental group ( $p < 0.05$ ). **Conclusion:** Insufficient research has been conducted on the development of resistance to lixisenatide. Despite its widespread use, observations have revealed that lixisenatide has adverse effects on the cerebral cortex of chick embryos, including cellular condensation and necrotic changes and mild distortion found in the cortex indicating degenerative changes in experimental groups C, D & E. Therefore, it is imperative that the administration of this vital medication is carefully considered to prevent neuronal complications.

**Keywords-** Lixisenatide, chick embryo, diabetes mellitus, cellular condensation, degeneration and necrotic changes

## Introduction:

The use of animal models in research is a common practice aimed at ensuring ethical research practices. Chicks are often preferred animal model due to their unique characteristics as they have a short gestation period of 21 days, which allows for faster experiments. Additionally, their large and easy to handle eggs make them ideal for research purposes. Chicks can be artificially incubated and are available year-round, having similar embryology to that of humans; making them an ideal choice for developmental research [1, 2]. Lixisenatide is a peptide that functions as a glucagon-like peptide-1 (GLP-1) receptor agonist. Comprising 44 amino acids, with amidation at the C-terminus at the 44th position and is effective in addressing type 2 diabetes mellitus by improving glycemic control, reducing weight, and mitigating cardiovascular risk in patients with this condition. [1, 3]. Lixisenatide is a GLP1 receptor antagonist,

means it mimicks the effects of the hormone GLP1 (glucagon-like peptide 1). GLP1 released in response to food intake and promotes insulin secretion, suppresses glucagon secretion, and slows down the speed of stomach emptying.[4] Lixisenatide delays the gastric emptying, suppress glucagon secretion, and stimulate insulin release. These mechanisms collaboratively contribute to the regulation of blood glucose levels. [5] a daily dose of 20mcg is recommended for patients with Type 2 diabetes mellitus. However, it is important to note that there are currently no clear-cut recommendations for dosage based on age and weight. While lixisenatide is an effective medication, there is currently no available data on the effects of lixisenatide on the developing cerebral cortex. Therefore, more research is needed to investigate the histopathological effects of lixisenatide on the cerebral cortex and ensure its safety and effectiveness for all patients.

### **Material and methods:**

Its an experimental study done at the Department of Anatomy, Santosh Medical College, Ghaziabad, Uttar Pradesh after obtaining institutional ethical clearance. The study aimed to investigate the effects of a particular experimentation on a specific parameter in two groups, a control group, and an experimental group. The expected mean  $\pm$  SD of the parameter for the control and experimental groups were found to be  $27\pm 5.32$  and  $32\pm 5.30$ , respectively, based on a literature survey and pilot study. To achieve appropriate sample size, G\*Power software was used, with an alpha level of 5% and a power of 95.36%, which resulted in an effect size of 1.961 and a sample size of 28 for each group, leading to a total sample size of 280.

### **Inclusion and exclusion criteria:**

The study only considered eggs that met the nutritional standards, like the eggs had to have a properly calcified shell, and an air cell located at the broader end of the egg without any clot. Eggs excluded from the study were with cracked shells due to improper calcification, those without an air cell at the proper place, and those with blood clots in the study.

### **Methodology:**

In this study, Fertilized eggs of the White Leghorn chicken (*Gallus domesticus*) were acquired from S.P. Hatchery and Poultry in Bhaupur Saharanpur, and Venkey's Hatchery on Shakumbhari Devi Road in Bhaguwala, Saharanpur, Uttar Pradesh.[1,2] The eggs were sourced from nutritionally healthy stock. Only healthy eggs were selected for injection, with any defective ones discarded after candling. A specially made wooden box painted black on the inside and with a bulb connection was procured for this purpose. On top of the box, a slot for the chick eggs was made. The eggs were scanned against the light to check for abnormalities and locate the air cells. [1 5]

### **Drug administration:**

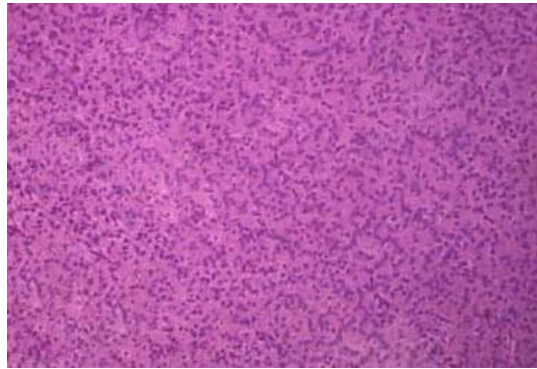
The recommended starting dose of lixisenatide is 10 mcg subcutaneously every day for 14 days. Then the maintenance dose of 20 mcg daily after the 14th day. The medication is available in two different strengths: a green single patient use prefilled pen having 50 mcg/ml in a 3 ml solution (providing 14 doses of 10 mcg each), and 100 mcg/ml in a 3 ml single patient use (14 doses of 20 mcg each)[1]. It's worth noting that 1 shot (0.2 ml) have 20 mcg of the drug from 100 mcg/ml prefilled pen. To prepare a solution of a drug, five shots, (.2ml) each containing (20mcg); i.e. 1 ml of the drug had (100 mcg), were added to 9 ml of distilled water. This resulted in a 10 ml solution containing 100 mcg of the drug (10mcg/ml). The solution was further diluted to achieve the desired concentration of the drug. For proper dose of the drug for new born chicks, the weight of chicks was measured and an average weight was calculated. To determine the amount of drug to be injected into a chick, the recommended human dose was used to calculate the dosage per kg for the chick's weight in relation to the human weight per kg. A dose-setting study was then carried out to determine the lethal dose 70 (LD70). Afterward, experimental groups were prepared with different drug concentrations below the LD70. On the fifth day of incubation, the experiment involved injecting the drug into the eggs, while the control group eggs were injected with an equal volume of distilled water. Before the injection, the eggs were wiped with a sterile gauze pad moistened with a 70% alcohol solution at broader end to remove external contaminants. A precise hole was drilled in the air cell's centre, to inject the drug. The solution was taken in a tuberculin syringe, and the needle was inserted horizontally into the air cell. The needle was wiped with a sterile gauze pad between each injection. After the injection, the eggs were sealed with molten wax and placed in the incubator for further development. On the 18th day of incubation, the chick embryos were carefully collected and dissected for examination after sacrifice [1, 2], and the cerebral cortex was examined by separating the brain and preserving it in a 10% formaldehyde solution. The histological characteristics were studied using a light and compound microscope.

### **Statistical analysis**

The data was analyzed using the SPSS software ® version 22.0. Descriptive statistics such as frequency and percentages were used to represent the data. For inferential statistics, the chi-square test was employed with a significance level of  $p < 0.05$  considered statistically significant.

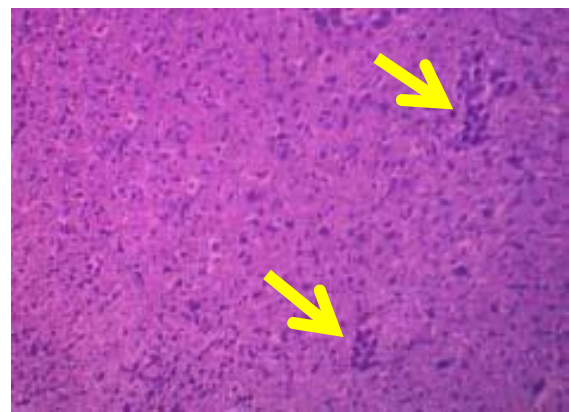
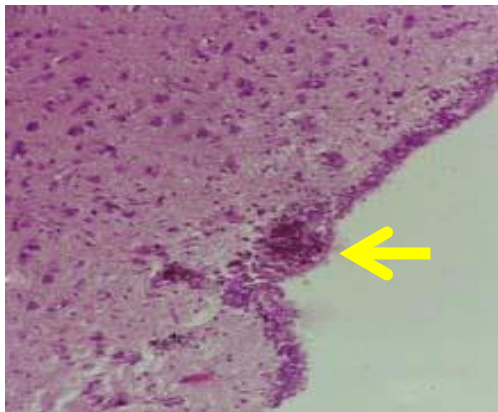
### **Result:**

**Figure 1(10X, H&E stain) - T.S. showing normal cerebral cortex in control group**



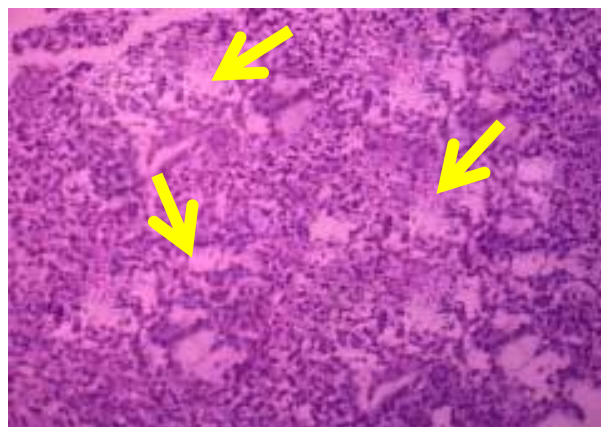
As per figure1. Indicates the normal architecture of developing chick embryo consisting of molecular layer

**Figure 2A (40X, H&E stain) & B (10X, H&E stain) - TS of Cerebral cortex showing cellular condensation and necrotic changes in experimental groups C, D and E**



As per figure 2 A & B, cellular condensation and necrotic changes were found in experimental group C, D & E.

**Figure 3 (10X, H&E stain) - TS of Cerebral cortex showing mild distortion in the cortex indicating degenerative changes in experimental group E**



As per figure 3, mild distortion in cerebral cortex was found indicating degenerative changes of cortex seen in experimental group E.

**Table 1- Summary of histopathology in Cerebral Cortex or no histopathology found in each Control group**

Group name	Total numbers in each Group	No histopathological changes	With histopathological changes	p-value
A <sup>c</sup>	28	28	0	P>0.05
B <sup>c</sup>	28	28	0	
C <sup>c</sup>	28	28	0	
D <sup>c</sup>	28	28	0	
E <sup>c</sup>	28	28	0	

Table 1 Normal saline dose increased in each control group, but the changes were not statistically significant (p>0.05)

**Table 2- Summary of histopathology in the Cerebral Cortex or no histopathology found in each Experimental group**

Group name	Total numbers in each Group	No histopathological changes	With histopathological changes	p-value
A	28	25	3	0.01*
B	28	24	4	
C	28	24	4	
D	28	23	5	
E	28	18	10	

As per Table 2. With each experimental group, as the dose of Lixisenatide increases, there are statistically significant histopathological changes in the cerebral cortex (p<0.05)

## Discussion

Lixisenatide and basal insulin together has been shown to be effective in treating type 2 diabetes. This treatment plan reduces PPG excursions during the day, leading to lower HbA1c levels. During a 24-week period, taking lixisenatide once daily showed an improvement in glycemic control and a noticeable effect after meals. The study did not find a significant increase in the risk of symptomatic or severe hypoglycemia, and weight loss was observed. Furthermore, Lixisenatide reduces A25-35-induced working memory impairment, reverses cytotoxicity in hippocampal cells, and protects Akt-MEK1/2 signaling pathway against A25-35 inhibition. [6]. Teratogens are substances that can disrupt the healthy development of a foetus during pregnancy, the developing tissues of the embryo shows structural or functional abnormalities in.[7] These harmful agents can affect a range of embryonic tissues, including the organ primordium, which may lead to the formation of a defective organ in the future[8]. In addition, teratogens can also impact maternal tissue and the placenta. In previous studies conducted by other researchers, it

was found that exposing a chicken embryo to different teratogens resulted in symptoms that were close to those observed in the current investigation. These symptoms included cellular degeneration [8], degenerative changes in brain development [9], [10].

To gain a better understanding of lixisenatide, further research could be conducted. For example, examining its effects on other organs in chicken embryos and conducting more immunohistochemistry research would be beneficial. Our study was limited to a chick embryo animal model, but the embryology of chick embryos is similar to that of mammals, including humans. Therefore, this study provides an idea about the drug's toxicity. [15] Hence, conducting additional research will aid in comprehending the impact of lixisenatide on human beings.

### **Conclusion**

Insufficient research has been conducted on the development of resistance to lixisenatide, a medication that is currently the preferred treatment for type 2 diabetes mellitus. Despite its widespread use, observations have revealed that lixisenatide has adverse effects on the cerebral cortex of chick embryos, including cellular condensation and necrotic changes and mild distortion in the cortex indicating degenerative changes. Hence, further research is necessary to understand the impact of lixisenatide, including examining the impact on other organs of chicken embryos and conducting further immunohistochemistry studies. In light of this, lixisenatide should only be administered in accordance with appropriate protocols and as medically indicated. Therefore, use of this vital medication carelessly may result to develop Neuronal complications. Therefore the medication must be administered appropriately and should be observed regularly.

### **Ethical Approval:**

Animal Ethic committee approval has been collected and preserved by the author(s)

### **References-**

1. Amit Kumar Srivastava, Yogesh Yadav, Ashok Kumar Gupta. Histopathological Changes In Kidneys Of Developing Chick Embryo On Exposure To Lixisenatide. J. Adv. Zool. [Internet]. 2023 Oct. 30 [Cited 2024 Apr. 17];44(S2):2601-8. Available From: <https://Jazindia.Com/Index.Php/Jaz/Article/View/1379>
2. Yogesh Yadav, Amit Kumar Srivastava, Ashok Kumar Gupta Lixisenatide Induced Congenital Anatomical Malformation And Histopathological Changes In Developing Chick Embryo Eur. Chem. Bull. 2023,12 (Special Issue 6),8134-8141  
Doi: [10.48047/Ecb/2023.12.Si6.7292023.01/09/2023](https://doi.org/10.48047/Ecb/2023.12.Si6.7292023.01/09/2023)

3. Vishram Singh, LK Mittal, RK Ashoka . Morphological and skeletal abnormalities induced by  $\alpha/\beta$  arteether on developing chick embryo. *Acta Medica International*. 2018;5(1):02-13.
4. R Singroha , SK Srivastava , P Chhikara. Effects of gentamicin on kidneys in developing chicks. *Eur J Anat*. 2012;16(2):119-26.
5. PE Natekar, Methotrexate induced gross malformations in chick embryo. *J Hum Ecol*. 2017;21(3);223-26.
6. P Rajendra et al , Biological effects of power frequency magnetic fields: Neuro chemical and toxicological changes in developing chick embryos, *Biomagnetic Research and Technology* 2014,2:1
7. Ulrich Werner, Effects of lixisenatide on postprandial glucose and gastric emptying – preclinical evidence *Journal of Diabetes and Its Complications* 28 (2014) 110–114
8. Pamir Erdinçler, The effects of high dose progesterone on neural tube development .In early chick embryo, *Neurology India*, vol. 54,no.2, April- June 2016, pp.178-18.
9. Paula L. McClean, Lixisenatide, a drug for type 2 diabetes, gives neuroprotective effects in a mouse model of Alzheimer's disease; *Neuropharmacology* 86 (2014) 241e258 .
10. Stern CD. The chick embryo past, present and future as a Yuji model system in developmental Biology, Elsevier Ireland limited, Mechanism of development. 2014;121(9):1011-13.
11. A Kotwani , chick embryo as an animal model for teratogenicity. *Indian J Physiol Pharmacol*. 2018;42(2):189-204.
12. Marta Prasek, Influence of nano particles of platinum on chicken embryo development and Kidney morphology, *Nano research letters* 2017,8:251.
13. Luc Van Gaal, Efficacy and safety of the glucagon-like peptide-1 receptor agonist lixisenatide versus the dipeptidyl peptidase-4 inhibitor sitagliptin in young (<50 years) obese patients with type 2 diabetes mellitus; *Journal of Clinical & Translational Endocrinology* 1 (2014) 31e37
14. Bo Ahrén, Equal improvement in glycaemia with lixisenatide given before breakfast or the main meal of the day; *Journal of Diabetes and Its Complications* 28 (2014) 735–741
15. Amit k Srivastava, Yogesh yadav , AK gupta, Histopathological Changes in Kidneys of Developing Chick Embryo on Exposure to Lixisenatide. *Korean Journal of Physiology and Pharmacology*, Volume 27, Issue 4, 2023.
16. Yasuo Terauchi, Evaluation of medical need among Japanese type 2 diabetes mellitus patient and efficacy of Lixisenatide treatment among Asian type 2 diabetes mellitus patients; *Diabetes & Metabolic Syndrome: Clinical Research & Reviews* 10 (2016) 23–28
17. Martin Lorenz , Claudia Pfeiffer , Axel Steinsträßer Effects of lixisenatide once daily on gastric emptying in type 2 diabetes — Relationship to postprandial glycemia *Regulatory Peptides* 185 (2013) 1–8.

18. Rajesh Kumar. Lavlesh Kumar Mittal. Ghazal Mittal ; Histopathological Changes in Kidneys of Developing Chick Embryo on Exposure to Artesunate. *Journal of Clinical and Diagnostic Research*. 2022 May, Vol-16(5): AC05-AC09
19. Kotwani A: Use of chick embryo in screening for teratogenicity . *Indian J Physiol Pharmacol*. 1998, 42:189-204.
20. Wilson JG, Andfraser FC: General principles and etiology. *Handbook of Teratology*. Wilson JG, Andfraser FC (ed): Springer, New York, NY; 1977. 1:357-85. [10.1007/978-1-4684-2850-6](https://doi.org/10.1007/978-1-4684-2850-6)
21. D Neubert , HJ Merker, E Kohler , R Krowke , HJ Barrach : Biochemical aspects of teratology. *Adv Biosci*. 1971, 6:575-622. [10.1016/B978-0-08-017571-3.50036-X](https://doi.org/10.1016/B978-0-08-017571-3.50036-X)
22. WJ Scott: Cell death and reduced proliferative rate . *Handbook of Teratology*. Wilson JG, Fraser FC (ed): Springer, Boston, MA; 1977. 2:81-98. [10.1007/978-1-4615-8933-4\\_4](https://doi.org/10.1007/978-1-4615-8933-4_4)
23. Kathryn Robinson , The Embryonic Development of Chickens and humans. 20 March 2013 208 Tweet.