

Original Research Article

Unveiling the Hindlimb Skeletal Structure of the Green-Winged Macaw (*Ara chloropterus*): A Detailed Analysis of Femur, Tibiotarsus, Tarsometatarsus, and Digits

ABSTRACT

In birds, the forelimb bones undergo modification to facilitate muscle attachment for flight, enabling the movement of wings up and down. Conversely, hindlimb bones primarily support walking and perching functions, necessitating evolutionary adaptations in their structure. Therefore, this study aims to document the gross anatomical features of hind limb bones in Green-winged Macaws, including the femur, tibio-tarsus, tarsometatarsus, and digits. The bones were sourced from six Green-winged Macaw carcasses undergoing post-mortem examination at the Department of Veterinary Pathology, Madras Veterinary College, Chennai. Preparation was conducted using the wet maceration technique. In the femur, the proximal end displayed a large, well-defined spherical head medially, accompanied by a small depression called the fovea capitis, and a distinct neck. The tibio-tarsus exhibited a small roughened area on its lateral border for fibula attachment, with a larger medial and smaller lateral condyle at the proximal extremity, along with a linear cinemal crest along the medial border. The fibula's distal extremity tapered into a free point, articulating at the caudolateral aspect of the tarsometatarsus. The tarsometatarsus displayed fused distal tarsals with metatarsals II, III, and IV, while Metatarsus I remained a separate bone, forming the base of the first toe. The proximal extremity of the tarsometatarsus featured two large concave articular facets for condyles from the distal extremity of the tibio-tarsus, and a facet for the distal end of the fibula caudolaterally. The Macaw's hind limb consisted of four digits, forming a zygodactyl foot arrangement.

Key words: Femur, Tibio-tarsus, Tarso-metatarsus, Digits, Green Winged Macaw and Gross Anatomy

1. INTRODUCTION

Any alteration in the anatomical attributes of animals is commonly perceived as adaptations to the particular habitats they inhabit. Among vertebrates, avian species exhibit a remarkable diversity in their choice of habitats. Parrots, scientifically classified as Psittaciformes or Psittacines, epitomize this versatility with their distinctive traits including a robust curved beak, erect posture, and clawed feet. This avian order encompasses four families, comprising approximately 410 species across 101 genera, predominantly inhabiting tropical and subtropical regions worldwide. The families encompass Psittaculidae (comprising Old World parrots), Psittacidae (encompassing African and New World parrots), Cacatuoidea (cockatoos), and Strigopidae (New Zealand parrots) [1]. These birds vary widely in size, ranging from small to large sized, often adorned with vibrant plumage, equipped with sturdy, sharply-curved bills for seed, fruit, and nectar consumption. They boast elongated tails and zygodactyl feet, featuring pointed claws conducive to an upright stance, spanning a length of 8–100 cm (3.2–39 inches). Macaws, renowned for their longevity, exhibit a lifespan of 30 to 45 years, exhibiting a proclivity for socialization to evade predators such as birds of prey, snakes, and primates. Possessing remarkable intelligence, they enjoy considerable popularity in aviculture. However, their present populations face declines attributable to factors such as trapping for the pet trade, habitat degradation, and competition from invasive species.

The avian skeletal structure is distinguished by its robustness and lightness, a feat achieved through fusion of elements and pneumatization. In particular, the forelimb bones undergo modifications to facilitate flight, serving as a foundation for the attachment of feathers. The bipedal locomotion observed in birds necessitates a unique anatomy of the legs and feet, tailored to suit diverse habitats and feeding behaviours. Notably, the limbs exhibit distinctive anatomical traits, with the pelvic limb fused distally to absorb the impact of take-off and landing [2]. Comprising elements such as the femur, tibiotarsus, fibula, tarsometatarsus, and four digits, these structures play pivotal roles in avian locomotion [3]. Among these, the

tibiotarsus stands out as the longest bone, particularly prominent in walking birds [4]. The fusion of the pelvis with the synsacrum, positioned anteriorly, effectively shifts the center of mass towards the leg, which bears the brunt of the body's weight. Parrots, renowned for their perching prowess rather than sustained flight, exhibit distinctive usage of their legs [5]. Due to the paucity of information concerning the gross anatomical features of hindlimb bones in Macaws, this study endeavours to fill this gap in understanding.

2. MATERIALS AND METHODS

In the present study, specimens comprising the femur, tibiotarsus, tarsometatarsus, and digits were procured from six carcasses of Green-winged Macaws submitted for post-mortem examination at the Department of Veterinary Pathology, Madras Veterinary College, Chennai. These avian subjects exhibited symptoms such as dyspnea, hematochezia, and resistance to conventional treatment over a duration of eight days. Upon post-mortem examination, hemorrhagic manifestations were discerned in the caecal tonsil, while no lesions were detected within the musculoskeletal framework during the necropsy procedure.

Subsequently, the legs were disarticulated from the os coxae and subjected to wet maceration to facilitate the removal of muscular and other soft tissues. Following this, treatment with a solution of 10 percent sodium bicarbonate was administered, followed by drying [6], in order to document the gross anatomical characteristics, thereof.

3. RESULT AND DISCUSSION

Within this study, the leg skeleton of the Green-winged Macaw comprised of a femur, patella, tibiotarsus, fibula, tarsometatarsus, and digits, as depicted in Fig-1.

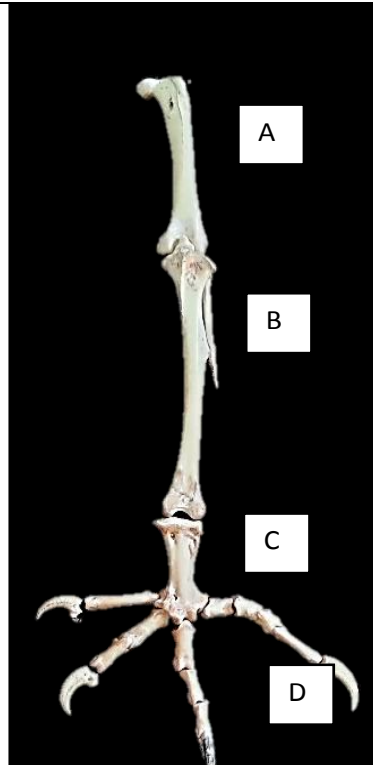
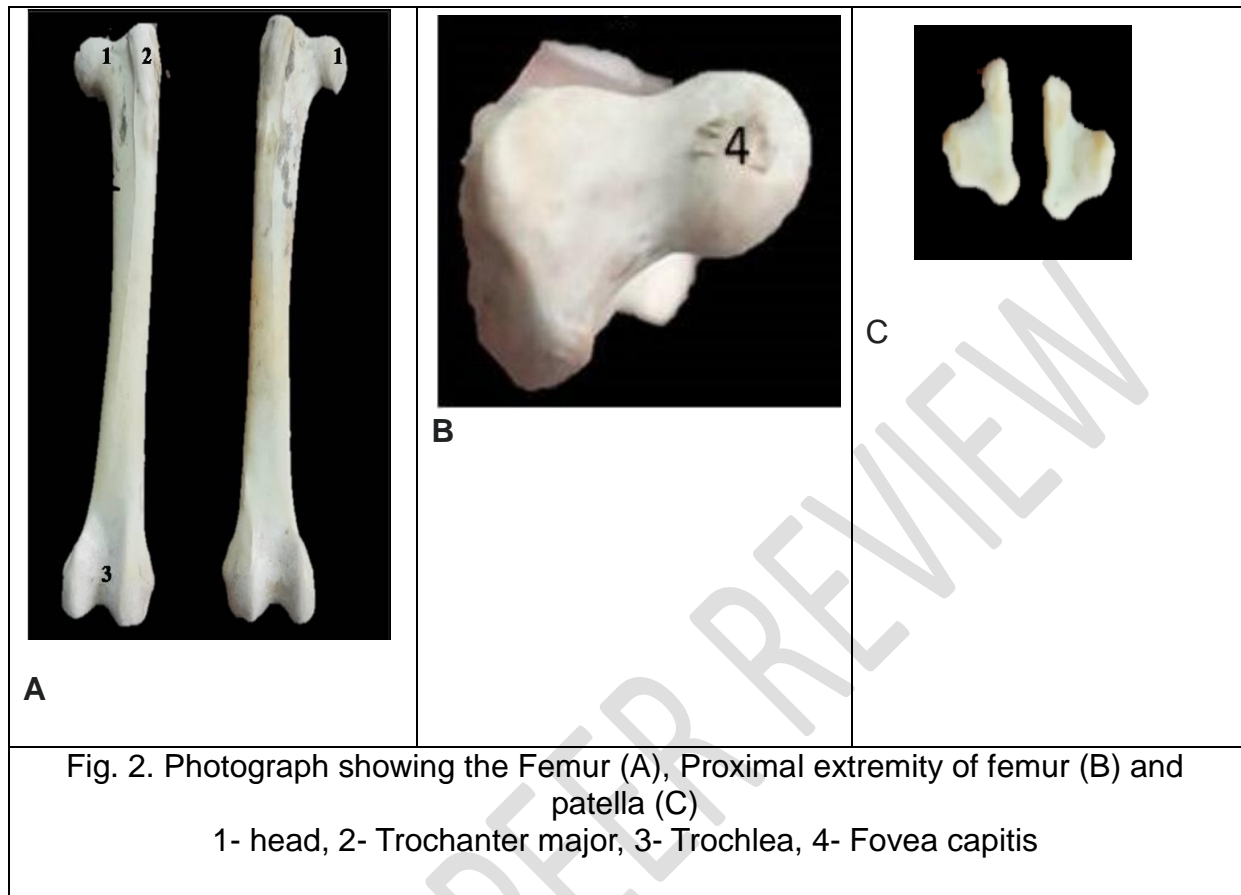


Fig. 1 Photograph showing the Hindlimb bones of Green Winged Macaw
A-Femur, B- Tibio-tarsus & Fibula, C- Tarso-metatarsus and D- Digits

3.1 Femur

Diverging from the morphology observed in mammals, the femur exhibited a stout, barrel-shaped structure, inclined downward and forward, between the hip joint above and the stifle joint below, consistent with observations in other avian species [7]. Characterized by a linear shaft housing four distinct surfaces and two extremities, as depicted in Fig-2. The proximal extremity featured a prominent spherical head, accompanied by a diminutive depression known as the fovea capitis, a feature commonly reported in avian species [8], though not discernible in Emus [9]. While the neck of the femur lacked clear demarcation in the Macaw under investigation, it exhibited well-defined delineation in Emus [9]. Comparatively, the trochanter major extended slightly beyond the head of the femur, akin to findings in guinea fowl [7], contrasting with the Ostrich, where the femoral head surpassed the level of the greater trochanter [10]. Notably, in certain avian species such as the Serpent Eagle and Brown Wood Owl [11], the greater trochanter and femoral head were aligned at an equal level, whereas in the White Cockatoo [6], their development

was less pronounced. Conversely, these features were notably well-developed in domestic fowl [12].



Distal extremity of femur had smaller medial and larger lateral condyles separated from trochlea by a wide intercondyloid groove. The medial condyle was placed at a lower level than the larger lateral condyle. The trochlear ridge was not observed on the medial condyle, whereas, the lateral condyle had trochlear ridge as it was mentioned by [10] in Ostrich. A small tubercle was present on lateral surface just an inch above the lateral condyle. Lateral condyle also presented a triangular articular area caudolaterally for articulation with head of fibula. The principal function of femur is to provide static support, as a cantilever and not as a pillar as in humans. It also has a function in the motion of the trunk during walking, and helps to maintain the trajectory of the centre of mass [13, 14]

Functionally, the femur assumes a pivotal role in providing static support akin to a cantilever rather than a pillar, as observed in humans. Furthermore, it plays a crucial part in trunk motion during ambulation and aids in maintaining the trajectory of the centre of mass, underscoring its multifaceted role in avian locomotion [13, 14].

3.2 Patella

The patella, a solitary, diminutive sesamoid bone, resembled a small pea in size and exhibited an irregular shape, as depicted in Fig-2. Notably, its lateral surface bore linear serrations, serving as attachment sites for the tendon of the thigh muscle, a feature also observed in guinea fowl [15]. Conversely, its medial surface was concave, featuring an articular facet for the tibia medially and the femur posteriorly, aligning with descriptions in guinea fowl specimens [7].

Functionally, the patella facilitated smooth articulation over the trochlea at the distal extremity of the femur, serving as a pivotal point for the tendon of insertion of femoro-tibialis muscle. This anatomical arrangement imbues the knee joint with leverage functionality, thereby contributing to avian locomotion [3]. It's worth noting that while a single patella was observed in the Green-winged Macaw under study, ostrich specimens demonstrated a double (proximal and distal) patella configuration [10].

3.3 Tibio-tarsus

The tibiotarsus, illustrated in Fig-3, represented the fusion of the tibia with the proximal row of tarsal bones at its distal end, standing as the longest bone in the Green-winged Macaw, a characteristic shared with fowl and pigeon specimens [12]. Along its lateral border, a slight bony prominence designated as the fibular crest provided attachment for the fibula, displaying variations in development across avian species, being less pronounced in fowl and absent in peacocks [16].

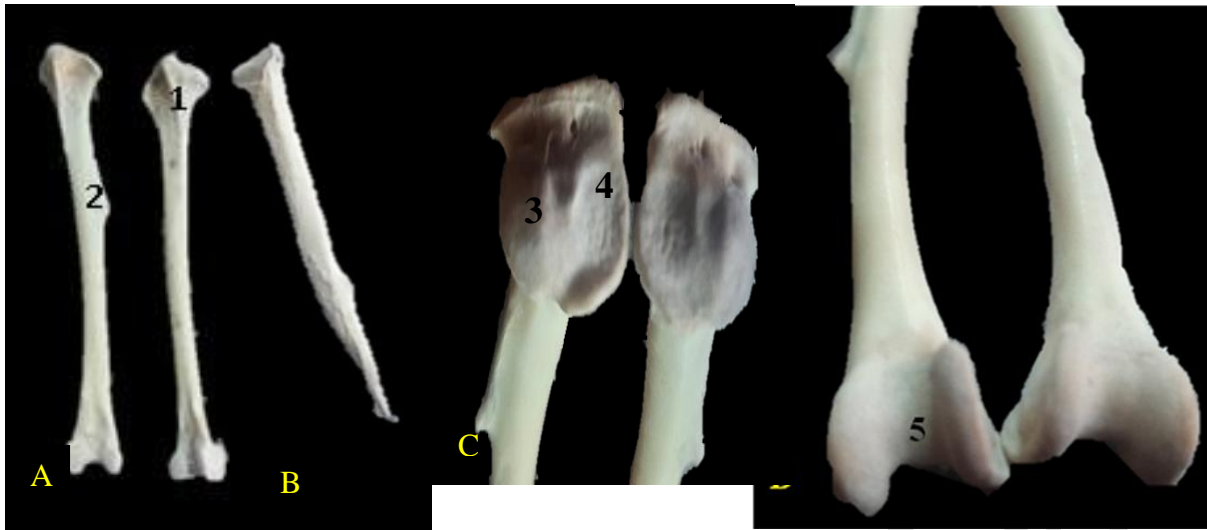

Fig 3 Photograph showing the Tibio-tarsus (A) & Fibula (B) Proximal (C) and Distal (D) extremities of Tibio-tarsus

1- Cinemal crest, 2- Fibular crest, 3- Lateral condyle, 4- Medial condyle, 5- Intercondyloid fossa

At its proximal end, the tibiotarsus featured larger medial and smaller lateral condyles, with a linear cinemal crest served as the point of origin for extensor muscles of the stifle joint, a feature noted in the White Cockatoo [6]. Notably, in turkeys, two cinemal crests were observed [17], while in ostriches, the cinemal crest exhibited extensive development [18]. The medial condyle manifested as a shallow depression, while the lateral condyle presented as a prominent bony protrusion, as depicted in Fig-3.

At the distal extremity, well-developed condyles and trochleae were observed, with the medial condyle being smaller than its lateral counterpart. These condyles were separated by a broad and shallow intercondyloid fossa. Additionally, the epicondyles of the medial and lateral condyles featured less pronounced areas for muscle attachment.

3.4 Fibula

The fibula exhibited a notably abbreviated length, characterized by a rudimentary shaft, as depicted in Fig-3, mirroring observations in the White Cockatoo [6]. It was affixed to the lateral border of the tibiotarsus, with its proximal end articulating with the caudolateral aspect of the lateral condyle of the femur. Along the lateral border of the tibiotarsus, the slender shaft of the fibula traversed, flanked by

the fibular crest, giving rise to a singular interosseous space, a common trait observed across domestic bird species [12]. However, certain avian specimens such as the Serpent Eagle, Brown Wood Owl, and Indian Eagle-Owl exhibited two interosseous spaces, proximal and distal [11].

Towards its distal end, the fibula tapered into a free point, articulating at the caudolateral aspect of the tarsometatarsus. Notably, in species such as ducks and guinea fowl, the fibular shaft extended only to the mid-shaft of the tibia [18, 7]. However, in the Serpent Eagle and Brown Wood Owl, the fibular shaft extended to the distal third of the tibial shaft [11]. It's important to highlight that the distal extremity of the fibula did not extend below the fibular crest, aligning with previous observations [20].

3.5 Tarsometatarsus

The tarsometatarsus, illustrated in Fig-4, stood out as a relatively diminutive bone compared to other hindlimb components, consistent with observations in the White Cockatoo [6]. Formed by the fusion of the second, third, and fourth metatarsals along with the distal row of tarsal bones, it mirrored the composition found in various domestic fowl species [10].

Its plantar surfaces exhibited concavity, while the dorsal surface appeared convex, featuring two nutrient foramina at its proximal extremity. Notably, the proximal end boasted two sizable concave articular facets, accommodating the condyles of the distal extremity of the tibiotarsus, along with a facet for the caudolateral aspect of the distal end of the fibula. At the distal extremity, three trochleae were present, demarcated by intercalated clefts, signifying the union of three metatarsal bones. Additionally, a bony canal separated the third and fourth digits, a feature absent in ostriches, emus, and guinea fowl [18, 7]. Furthermore, the first metatarsal appeared as a small elongated bone attached at the distal extremity on the medial side, positioned above the first digit [12, 3].

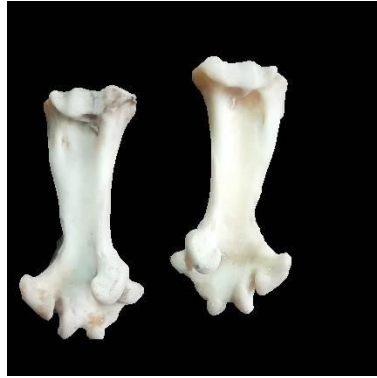

Fig 4 Photograph showing the Tarso-metatarsus with trochlea in the distal extremity

The shape of the tarsometatarsus varied according to species locomotion habits, with an elongated metatarsus providing extra leverage for running or take-off during flight [3]. Short tarsometatarsus structures, as observed in parrots, facilitated adept climbing and food manipulation, albeit resulting in a characteristic waddling or rolling gait, particularly notable in species like Macaws, which utilize the caudal tarsometatarsus as well as the foot during ambulation [20].

3.6 Digits

The Green-winged Macaw displayed a zygodactyl foot structure, featuring the first, second, third, and fourth digits, each equipped with two, three, four, and five phalanges, respectively (Fig-5). Consistent with zygodactyl species, the first and fourth digits were oriented caudally, while the second and third digits faced cranially [3]. Interestingly, the ostrich exhibited only two digits (digits III and IV), while the emu possessed three digits [18]. Notably, in the ostrich, the fourth digit lacked a fifth phalanx [22].

As one progressed towards the fourth phalanx, the number of phalanges increased, culminating in a hook-shaped claw at the distal phalanx, enveloped by horny skin in life, a characteristic shared with the White Cockatoo [6]. Specifically, the first and fourth digits were noted to face backward, in accordance with findings reported in Macaws [23] and Budgerigars [24], while the second and third digits exhibited a forward orientation.




Fig 5 Photograph showing the Tarso-metatarsus with digits

4. CONCLUSION

The revelations of this study elucidate that the gross anatomical intricacies of the leg skeletal structure in the Green-winged Macaw encompass the femur, patella, tibiotarsus, tarsometatarsus, and digits, aligning seamlessly with those observed in other *Zygodactyl* species. These findings serve to underscore the anatomical modifications present in the leg bones of the Green-winged Macaw, which plausibly underlie the robustness of its feet, adeptly employed for both climbing and pendulous movement. Furthermore, this species exhibits a remarkable utilization of its feet for the manipulation of food and assorted objects, evincing a level of manual dexterity akin to that demonstrated by humans employing their hands.

REFERENCES

1. George O, Butchart SHM, Andy S, Guzman IM, Cunningham R, Brightsmith DJ and Heinsohn R. Ecological and socio-economic factors affecting extinction risk in parrots. *Biodiversity and Conservation*. 2016. 25 (2): 205–223.
2. Rajani CV, Patki HS, Wilson HM and Surjith K. Comparative morphological studies of the pelvic limb bones in ostrich (*Struthio camelus*), emu (*Dromaius novaehollandiae*), domestic fowl (*Gallus gallus domesticus*) and duck (*Anas platyrhynchos domesticus*). *Indian J Animal Res.*, 2019., 53(11):1445–9.
3. Malley BO. *Clinical Anatomy and Physiology of Exotic Species*. Chapter 6, Avian anatomy and physiology: 2005, 97-161.

4. Rajalakshmi K, Sridevi P and Siva Kumar M. Gross morphological and morphometric studies on the femur, tibiotarsus and fibula in Emu (*Dromaius novaehollandiae*). J Pharm Innov 2020., 9(1):207-210
5. Abourachid A and Hofling E. The legs: A key to bird evolutionary success. J. Ornithol, 2012, 153(1).
6. Sreeranjini AR, Ashok N, Maya S, Lucy KM, Indu VR, Sunilkumar NS and Sumena KB. Gross Anatomical Studies on the Pelvic Limb Bones of White Cockatoo (*Cacatua alba*). J. Vet. Anim. Sci., 2020.,51 (1): 86 – 90.
7. Onwuama KT, Ibe CS, Omowunmi LK, Kigir ES, Jaji AZ and Salami SO. Hindlimb Skeletal Morphology of the Helmeted Guinea Fowl (*Numida Meleagris*). Folia Veterinaria, 2023., **67** (1): 24-34.
8. McLelland J. A Colour Atlas of Avian Anatomy. Wolfe Publishing Ltd, England 1990,42-43.
9. Kumar P and Singh G. Gross Anatomy of Wing and Pelvic Limb Bones in Emu (*Dromaius novaehollandiae*).Indian Journal of Veterinary Anatomy, 2014, **26** (2): 82-86.
10. Kassem MA, Reem R, Tahon K, Khalil M and Medhat A, Morphometric studies on the appendicular bony skeleton of the ostriches (*Struthio Camelus*). BMC Vet Res, 2023, 19 (109): 1-14.
11. Choudhary OP, Priyanka PC, Kalita RS, Arya TK, Rajkhowa PJ, Doley A and Kalita K. Comparative gross anatomical studies on pelvic limb long bones of crested serpent eagle (*Spilornis cheela*) and brown wood owl (*Strix leptogrammica*).Ind. J. Anim. Res., 2020., 55 (3): 277–282.
12. Nickel R, Schummer A and Seiferle E. Anatomy of the Domestic Birds.1st Edn. Verlag Paul Parey, Berlin, Hamburg. 1977; 1:16-17.
13. Abourachid A, Hackert R, Herbin M, Libourel PA, Lambert F, Gioanni H, Provini P, Blazevic P and Hugel V. Bird terrestrial locomotion as revealed by 3D kinematics. Zoology 2011, 114:360–368.
14. Provini P, Goupil P, Hugel V and Abourachid A. Walking, paddling, waddling: 3D kinematics of Anatidae locomotion (*Callonetta leucophrys*). J Exp Zool, 2012
15. Maierl J, Liebich H, Konig HE and Korbel R. Pelvic limb (*membrum pelvinum*). In Avian Anatomy Textbook and Colour Atlas. 2nd Edn., 5M Publishing Ltd,

Benchmark House, 8 Smithy Wood Drive, Sheffield, S35 1QN, UK,
2016.62–82

16. Sreeranjini AR, Ashok N, Indu VR, Lucy KM, Maya S and Syam KV. Morphological studies on the femur, tibiotarsus and fibula of peahen (*Pavo cristatus*) Tamilnadu J. Vet. Anim. Sci., 2013.,9: 248-252.
17. Al-Sadi S. Comparative morphometric study of shank bone in the tom (Meleagris gallopavo) and local cock (*Gallus banikaval*). Iraqi J. Vet. Sci., 2012, 26: 57-64
18. Chukkath R, Harshad P, Helna W and Kalarippambath S. Comparative morphological studies of the pelvic limb bones in ostrich (*Struthio camelus*), emu (*Dromaius novaehollandiae*), domestic fowl (*Gallus gallus domesticus*) and duck (*Anas platyrhynchos domesticus*). Ind. J. Anim. Res., 2019.,53 (11) :1445–1449.
19. Sarma K, Suri S and Sasan JS. Gross anatomical studies on os coxae of Indian eagle owl (*Bubo bengalensis*). Explor. Anim. Med. Res., 2018., 2: 208–210
20. Harcourt-Brown N. Anatomy and Physiology of Parrots. Thesis submitted for FRCVS at Liverpool University Veterinary College. Chapter 2,2023
21. Harcourt-Brown, NH Pelvic limb problems. In P. H. Benyon (ed.), BSAVA Manual of psittacine birds. Gloucester, UK: BSAVA, 1996, 123–133.
22. Zhang R, Wang H, Zeng G, Zhou C, Pan R, Wang Q and Li J. Anatomical study of the ostrich (*Struthio camelus*) foot locomotor system. Ind. J. Anim. Res., 2016,50 (4): 476–483.
23. Abramson J, Speer BL and Thomsen JB. The Large Macaws, Their Care and Breeding, Rain tree Publications 1999: CA.
24. Botelho JF, Smith-Paredes D, Nunez-Leon D, Soto-Acuna S and Vargas AO. The developmental origin of zygodactyl feet and its possible loss in the evolution of passeriformes. Proc. R. Soc. B, 2014, 281.