

Evan's syndrome- hemolytic anemia with thrombocytopenia in a Labrador dog – A case report

ABSTRACT:

A seven-year-old Labrador retriever intact male dog was presented to the Referral Veterinary Polyclinic, Indian Veterinary Research Institute, Izatanagar with a history of inappetance, melena, and petechial hemorrhages on the ventral abdomen and treated by a local veterinarian for a prolonged period of time. Clinical examination showed pale mucous membranes, peripheral lymphadenopathy, and mild hepatomegaly. A Complete blood count revealed anemia, leukopenia, and thrombocytopenia and serum biochemistry showed hypoalbuminemia and hypoproteinemia. The dog was suspected of having a haemoprotozoan infection, and a thin peripheral blood smear was submitted to the Division of Parasitology, Indian Veterinary Research Institute, Izatanagar, Bareilly, for examination. A blood smear was screened for haemoprotozoan examination using Giemsa's stain, which showed positivity for *Babesia vogeli*. An abdominal ultrasound confirmed hepatic enlargement. The blood clotting profile reveals an increase in activated partial thromboplastin time and prothrombin time. The dog's blood sample tested negative for *Babesia vogeli*, *B. gibsoni*, *E. canis*, and *H. canis* by multiplex PCR; this could be because of prior initiation of antibiotics. A peripheral blood smear showed elevated spherocytes count and saline agglutination test was positive. Based on history, clinical examinations, laboratory findings and cytological examinations the case was tentatively diagnosed as chronic case of tick fever with concomitant Evans syndrome. A blood transfusion was performed and around 300 ml of whole blood was infused. Treatment was initiated with triple antibiotic therapy and an immunosuppressive dose of steroids, but after 4 weeks, the dog succumbed to the condition. Further research is required to optimize treatment regimens for dogs with Evan's syndrome, as the prognosis is uncertain.

1. INTRODUCTION

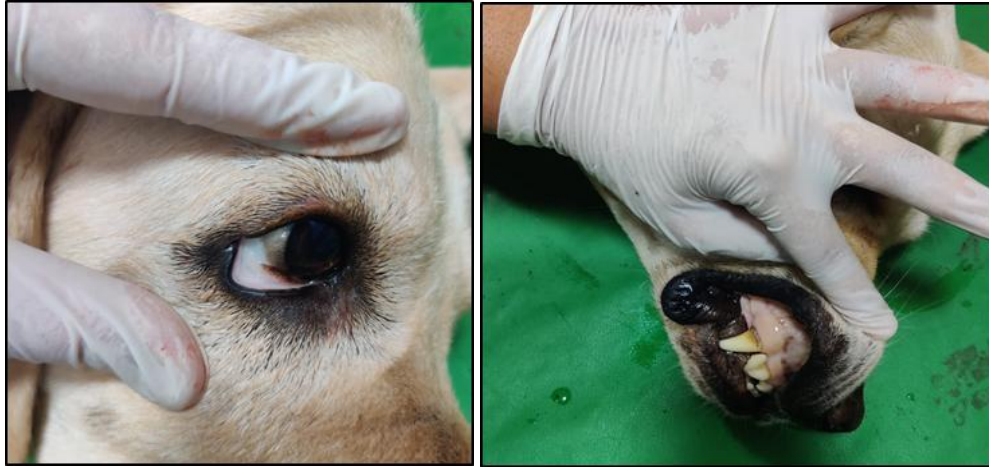One of the most fatal haemoprotozoan infections in dogs that is spread by ticks is babesiosis. The most common *Babesia* species in dogs are *B. canis*, *B. vogeli*, *B. rossi* and *B.*

gibsoni, which are intracellular protozoan parasites of canine erythrocytes [1]. *B. canis* is indigenous to Southern Europe, America, Asia, and South Africa, but *B. gibsoni* is found in the Middle East, Northern Africa, and South Asia [2]. Babesia infection produces autoimmune disorders in dogs, such as immune-mediated haemolytic anaemia (IMHA) and immune-mediated thrombocytopenia (ITP), which can develop separately or concurrently. If they present together then it is called as Evans Syndrome [3]. Evan's syndrome is named after Robert Evans, who originally documented it in humans in 1951 [4]. It appears similarly in dogs, although with variable clinical presentations and findings. Evans syndrome with Babesia in canines destroys RBCs, platelets, and causes oxidative stress, and endothelial damage [5]

B. vogeli in a dog is spread by brown dog tick that is *Rhipicephalus Sanguineus* and is indigenous to Africa, America, Asia, Australia, and Europe [6]. *B. vogeli* is considered to be mildly pathogenic, causing subclinical or mild disease [7]. Clinical findings include depression, weakness, anorexia, fever, lymphadenomegaly, splenomegaly, anaemia, thrombocytopenia, jaundice. These symptoms are similar to those observed with other forms of Babesia [8]. Although severe infection can develop in dogs infected with other species, systemic inflammatory response syndrome (SIRS), multiple organ dysfunction syndrome (MODS), refractory hypotension and septic shock are common findings [9]. In this study, a dog infected with *Babesia vogeli* was diagnosed conventionally, and the prevalence and control methods in India were discussed.

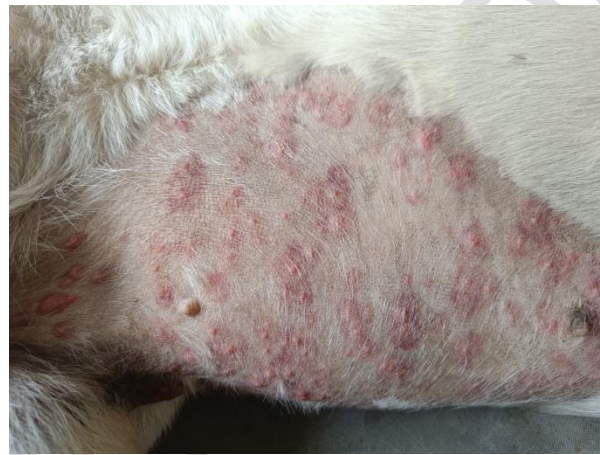Clinical presentation of animal

A seven-year-old Labrador retriever intact male dog was presented with a history of inappetance, melena, lethargy and petechial hemorrhages on the ventral abdomen to the Referral Veterinary Polyclinic, Indian Veterinary Research Institute, Izatanagar and treated by a local veterinarian for a prolonged period of time. Thorough clinical examination of the dog showed enlargement of peripheral lymph node, pale conjunctival mucous membrane, petechial hemorrhages on the body and hepatomegaly evident on abdominal palpation. Due to suspicion of tick fever, thin blood smear was sent of Division of Parasitology, Indian Veterinary Research Institute, Izatanagar, Bareilly for haemoprotozoan examination.



(A)

(B)



(C)

Figure 1: (A) Pale conjunctiva (B) Pale mucous membrane (C) Petechial hemorrhages on the ventral abdomen

Laboratory examination:

A 1mL blood sample was obtained in an EDTA vial and 2mL in serum vial and sent to the laboratory. A routine haematology revealed anaemia (Hb: 2.6mg/dL, Erythrocytes: 0.96×10^6) and thrombocytopenia (25,000/cmm). Serum biochemistry examination showed decrease in total protein (3.94g/dL) count while kidney values were all within normal range. Blood clotting profile revealed increase in activated partial thromboplastin time (20 second) and prothrombin time (12.2second).

Diagnostic imaging:

Ventral abdominal area was shaved and prepared for abdominal ultrasound. Abdominal ultrasound examination was carried out with the help of Curvilinear transducer (2.5-5MHz frequency) showed enlargement in liver parenchyma. No other significant findings were reported on abdominal ultrasound.

2. MATERIALS AND METHODS

Following one minute of immersion in methanol, the thin blood smear was subjected to Giemsa's stain, diluted at a ratio of 1:10 with water to create a working solution, and left for 40 minutes. Subsequently, the slide underwent rinsing with tap water, drying, and focusing under a compound binocular light microscope with oil immersion. Microscopic examination of thin blood smear stained with Giemsa stain showed presence piroplasms of *Babesia vogeli* in the erythrocytes. Spherocytes were also observed in the smear indicating autoimmune hemolytic anemia.

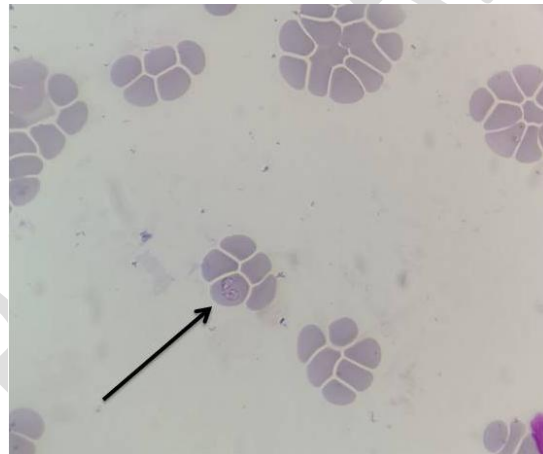


Figure 2: Piroplasm of *Babesia vogeli* in erythrocyte of dog

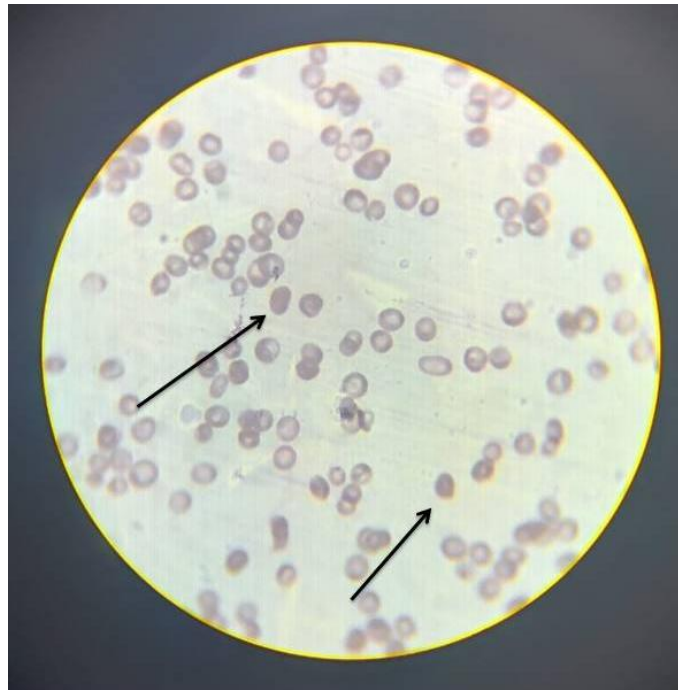


Figure 3: Spherocytes in Giemsa stained blood smear

3. TREATMENT PROTOCOL:

Based on history, clinical examination and laboratory investigation findings, the present case was tentatively diagnosed as a case of Evans syndrome associated with *Babesia vogeli*. Therapy was started with Diminazene aceturate at the dose rate of 5mg/kg B.wt. deep intramuscularly and repeated after 14 days. Also triple antibiotic therapy was initiated using Doxycycline at the dose rate of 10 mg/Kg. B.wt once daily orally for 21days, Clindamycin at the dose rate of 11 mg/Kg. B.wt twice daily orally for 21days, and metronidazole at the dose rate of 10 mg/Kg. B.wt twice daily orally for 21days along with Pantoprazole at the dose rate of 1 mg/Kg. B.wt once daily orally for 21 before food. Immunosuppressive therapy with prednisolone at the dose rate of 1 mg/Kg. B.wt once daily orally at tapering dose was initiated. Fluid therapy, styptics, hematinics, and carioca papaya extract were all used as supportive treatments. To get rid of tick infestations, Fipronil and S-Methoprene were administered topically.

Blood transfusion: Heparin (5–10 units/ml of blood) was used as an anticoagulant to draw 300 ml of whole fresh blood from the donor. Blood samples from donors and recipients were

compatible, as demonstrated by major and minor cross-matching. The recipient dog received 300 milliliters of blood over three hours. No adverse transfusion reaction was seen.

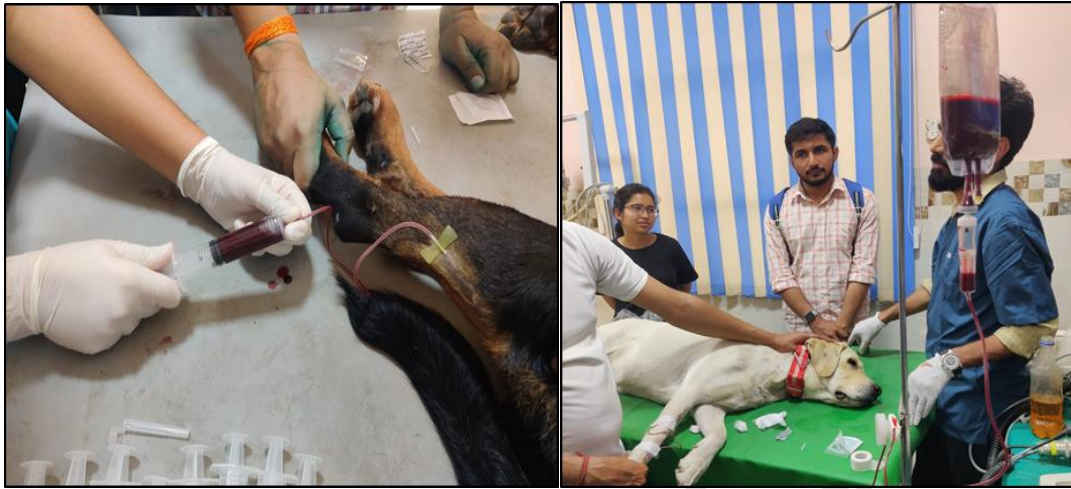

Figure 4: Blood transfusion

4. DISCUSSION

Immune-mediated thrombocytopenia (ITP), alternatively termed Evans syndrome or IMP, arises from various origins, either primary or secondary. Primary immune thrombocytopenia (IMTP) lacks a discernible underlying cause, while secondary IMTP can arise from various potential triggers, such as neoplasia, tick-borne illnesses (like ehrlichiosis and babesiosis), certain medications (including sulfa antibiotics), vaccination, and blood transfusions. Unlike immune-mediated hemolytic anemia (IMHA) which targets red blood cells, ITP manifests with the body's immune system excessively targeting platelets, leading to their depletion at a pace surpassing their production in the bone marrow. Evan's syndrome is a rare autoimmune disorder that poses significant diagnostic and therapeutic challenges in veterinary medicine [10]. Researchers claim that 30% of animals with IMTP also develop IMHA at the same time [11].

In this case, secondary IMTP was suspected. Imaging examination such as abdominal ultrasound was performed to detect any tumors, but showed no signs, and the root cause remained unidentified. The conclusive diagnosis of IMTP depends on the detection of anti-platelet antibodies, but these tests are not commonly accessible and cannot differentiate between primary and secondary IMTP. Hence, treatment may begin based on a presumptive diagnosis.

Immunosuppressive and immunomodulatory medications are the mainstay of IMTP treatment. The most commonly prescribed class of immunosuppressive medications for treating IMTP is corticosteroids, predominantly prednisone at a dosage of 1 to 1.5 mg/kg, every 12 hours. Prednisone offers several advantages, including its quick onset of action in managing the disease, ease of both injection and oral administration, and relatively low cost. It functions by hindering macrophage activity in platelet destruction and can also enhance capillary resilience to bleeding. Improvement in symptoms typically occurs within 2 to 11 days of initiating treatment. In cases where there is a positive clinical response, the dosage can be gradually reduced by 25% every 2 weeks, with the objective of maintaining normal platelet levels once the immunosuppressive drugs are discontinued. Apart from utilizing immunosuppressive medications for medical treatment, administering blood transfusions could help replenish platelet levels in cases of IMTP.

Antiprotozoal therapy with triple antibiotics was used for treating underlying haemoprotozoan infection with *Babesia vogelli*. The treatment regimen employed use of three antibiotics—clindamycin, metronidazole, and doxycycline—which has proven to be more efficacious in treating canine babesiosis. Clindamycin, a derivative of lincomycin, enhances both cellular and humoral immunity by targeting *Babesia sp.*, demonstrating effectiveness against babesiosis. Doxycycline, belonging to the tetracycline class, has been noted for its preventive action against *Babesia canis* infection, while metronidazole, an anti-trichomonal agent, exhibits therapeutic efficacy against *Babesia gibsoni* infection. The clinical symptoms showed rapid improvement upon commencement of treatment, and animal succumb to the condition. This suggests that resistance to the combination therapy had not developed yet and that parasitemia can be effectively suppressed with successful implementation of this combination protocol.

5. CONCLUSION

In conclusion, the case of the seven-year-old Labrador retriever presented with inappetence, melena, and petechial hemorrhages was diagnosed as a chronic case of tick fever with concomitant Evans syndrome based on comprehensive history, clinical examinations, laboratory findings, and cytological examinations. Despite treatment initiation including triple antibiotic therapy and immunosuppressive doses of steroids along with a blood transfusion, the dog's condition deteriorated, and it ultimately succumbed to the illness after four weeks. The negative results of multiplex PCR testing for specific pathogens could be attributed to prior antibiotic administration. This case underscores the complexity and challenges associated with managing

canine Evans syndrome, highlighting the need for further research to optimize treatment regimens and improve prognostic outcomes in affected dogs.

REFERENCES:

1. Breitschwert E. Babesiosis. *Clinical Microbiology and Infectious Diseases of the Dog and Cat*. Philadelphia: WB Saunders. 1984;796:805.
2. Salem NY, Farag HS. Clinical, hematologic, and molecular findings in naturally occurring *Babesia canis vogeli* in Egyptian dogs. *Veterinary Medicine International*. 2014 Feb 11;2014.
3. Norkus CL, editor. *Veterinary technician's manual for small animal emergency and critical care*. John Wiley & Sons; 2018 Sep 13.
4. Evans RS, Takahashi K, DUANE RT, Payne R, Liu CK. Primary thrombocytopenic purpura and acquired hemolytic anemia: evidence for a common etiology. *AMA archives of internal medicine*. 1951 Jan 1;87(1):48-65.
5. Di Cicco, M.F and Birkenheuer, A.J. 2012. Canine Babesiosis - Peer Reviewed. *NAVC Clinician's Brief*. July 31-35.
6. Uilenberg G. Babesia—a historical overview. *Veterinary parasitology*. 2006 May 31;138(1-2):3-10.
7. Koster LS, Lobetti RG, Kelly P. Canine babesiosis: a perspective on clinical complications, biomarkers, and treatment. *Veterinary medicine: research and reports*. 2015 Apr 10;119-28.
8. Wang J, Zhang J, Kelly P, Zheng X, Li M, You J, Huang K, Qiu H, Wang Y, Zhang R, Li J. First description of the pathogenicity of *Babesia vogeli* in experimentally infected dogs. *Veterinary parasitology*. 2018 Apr 15;253:1-7.
9. Matijatko V, Kiš I, Torti M, Brkljačić M, Kučer N, Rafaj RB, Grden D, Živičnjak T, Mrljak V. Septic shock in canine babesiosis. *Veterinary parasitology*. 2009 Jun 10;162(3-4):263-70.
10. Momin M, Aluri A, Reddy S, Pasupala NK. Evans' syndrome-haemolytic anaemia with thrombocytopenia-a rare autoimmune disorder. *Journal of Clinical and Scientific Research*. 2017 Oct 1;6(4):237-40.

11. Apps C. A case of immune-mediated thrombocytopenia, possibly Evans syndrome, in a neutered Rottweiler dog. Can Vet J. 2023 Apr;64(4):379-382. PMID: 37008642; PMCID: PMC10031779.

UNDER PEER REVIEW